

## VIDEOS IN CLINICAL MEDICINE

## Basic Laceration Repair

Todd W. Thomsen, M.D., Derek A. Barclay, M.D., and Gary S. Setnik, M.D.

From the Department of Emergency Medicine, Mount Auburn Hospital, Cambridge, MA (T.W.T., G.S.S.); the Department of Emergency Medicine, Brigham and Women's Hospital, Boston (D.A.B.); and the Division of Emergency Medicine, Harvard Medical School, Boston (T.W.T., D.A.B., G.S.S.). Address reprint requests to Dr. Thomsen at the Department of Emergency Medicine, Mount Auburn Hospital, 330 Mount Auburn St., Cambridge, MA 02238, or at [tthomsen@mah.harvard.edu](mailto:tthomsen@mah.harvard.edu).

N Engl J Med 2006;355:e18.

Copyright © 2006 Massachusetts Medical Society.

**INDICATIONS**

Lacerations are among the most common reasons for visits to emergency departments, with over 11 million wounds treated each year in the United States.<sup>1</sup> Although most lacerations will heal without treatment, repair of these injuries reduces infection, scarring, and patient discomfort.<sup>2</sup> Various methods may be used for laceration repair. Suturing is the most common method of wound closure and is demonstrated in the accompanying video and discussed in detail here. Wound staples, frequently used on lacerations involving the scalp, torso, arms, legs, hands, and feet, offer the advantage of rapid placement but do not allow for the meticulous wound-edge approximation afforded by suturing. Tissue adhesives, such as 2-octylcyanoacrylate, are less painful and more quickly applied than sutures or staples and are ideal for small lacerations that are not subject to large degrees of tension.<sup>2</sup> Tissue tapes (e.g., Steri-Strips, 3M) may be used for superficial or partial-thickness lacerations but are not suitable for lacerations that are subject to considerable tension.

**CONTRAINDICATIONS**

Not all lacerations are suitable for primary closure. Some should be allowed to heal by secondary intention (i.e., granulation and reepithelialization) or should, in specific cases, be repaired 3 to 5 days after injury (delayed primary, or tertiary, closure). The decision to suture a wound must be made on an individual basis and take numerous factors into consideration.

The interval between injury and evaluation is important, since delays in repair may increase the risk of infection. The location of the wound and the degree of contamination may affect the acceptable interval between injury and repair. For example, some contaminated wounds on the hands or feet may require closure within 6 hours, whereas some facial or scalp lacerations can often be safely repaired more than 24 hours after injury. The decision to suture a wound must be made on an individual basis, and the interval between injury and repair may be shortened for patients with impaired host defenses.<sup>3</sup>

Secondary closure should be strongly considered for wounds that are grossly contaminated and for most puncture and bite wounds to the extremities. Delayed primary closure may be used for large or cosmetically important lacerations that are not suitable for primary repair.<sup>1</sup> After 3 to 5 days, the patient's natural defenses reduce the bacterial load, thereby reducing the risk of infection.<sup>3</sup>

Consultation with a specialist should be considered for wounds involving substantial loss or destruction of tissue, complicated lacerations on the hands or face, or wounds thought to involve serious injury to an underlying structure.

**EQUIPMENT**

Many institutions stock prepackaged laceration trays that contain most of the necessary equipment. Preparatory equipment includes a skin-cleansing agent such as

chlorhexidine or povidone–iodine, sterile gauze, local anesthetic, a 5- or 10-ml syringe and a 25- to 30-gauge needle for injection of the anesthetic, saline solution, a 30- to 60-ml syringe with a splash guard for irrigation, a sterile bowl, and a sterile drape. For suture placement, you will need a needle holder, a toothed (Adson–Brown) forceps, suture scissors, and appropriate suture material.

One percent lidocaine is an appropriate anesthetic for most lacerations. Bupivacaine may be used in situations requiring an anesthetic with an extended duration of action (up to 4 to 6 hours) (Table 1). The addition of epinephrine to the anesthetic extends the duration of action, reduces bleeding, increases the amount of anesthetic that can be used, and increases the intensity of the block produced.<sup>3</sup> However, solutions containing epinephrine should be avoided in areas with a single blood supply, such as the nose, pinna of the ear, and penis. Dilute (1:200,000) solutions of epinephrine may be used on lacerations of the fingers if vascular perfusion is otherwise normal.

For percutaneous stitches, nonabsorbable monofilament nylon or polypropylene suture material should be used. Absorbable sutures (such as those made of polyglycolic acid or polyglactin-910) are intended for subcutaneous (deep) repairs, which are not discussed in this review. Size 6.0 suture material is appropriate for facial lacerations, whereas size 3.0, 4.0, or 5.0 should be used on the torso, arms, legs, hands, and feet. Larger suture material should be used in lacerations that are subject to high degrees of static or dynamic skin tension.

A wide variety of types and sizes of needles are available. Reverse-cutting needles are preferred for percutaneous sutures. These needles have a triangular cross section, which forms three cutting edges along the length of the needle. Reverse-cutting needles have the third cutting edge along the outer convex side of the needle, as opposed to the conventional cutting needles in which the third cutting surface is on the inner side. The design of the reverse cutting needle facilitates proper depth of suture placement and prevents the needle from cutting the tissue that is closest to the wound.<sup>4</sup>

The needle should be large enough to pass through the required depth and width of the tissue without difficulty.<sup>3</sup> The use of needles that are too large or too small may complicate the repair.

#### PREPARATION

Explain the procedure to the patient, and then place all equipment on a bedside table within easy reach. Have the patient lie down on a stretcher, with the laceration fully exposed and the area well lit. Wash your hands with soap and water before beginning the laceration repair. Wear gloves and a protective face shield throughout the procedure. Assess and document the neurovascular status of the area, espe-

**Table 1. Local Anesthetics Used in Laceration Repair.\***

Agent	Duration of Action	Maximum Dose	Maximum Volume for a 70-kg Patient
	<i>min</i>	<i>mg/kg of body weight</i>	<i>ml</i>
1% Lidocaine	30	4.5	31.5
1% Lidocaine with epinephrine	60–240	7	49
0.25% Bupivacaine	240–480	3	84

\* A 1% solution is equal to 1 g of agent per 100 ml of diluent. Therefore, each milliliter of a 1% solution of lidocaine contains 10 mg of the agent. Data are from Trott.<sup>3</sup>

cially that distal to the repair site on an extremity, before anesthetizing or manipulating the wound.

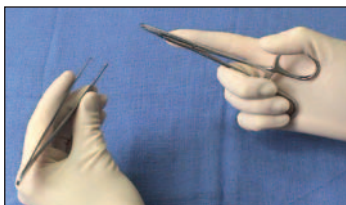Apply a skin-cleansing agent, such as chlorhexidine or povidone-iodine, in a circular fashion around the laceration. Start from the wound edges and gradually work outward. Do not introduce antiseptic solution directly into the wound, since many contain detergents that are toxic to the subcutaneous tissues and could interfere with wound healing.<sup>3</sup> Hair around a laceration does not need to be shaved before repair — in fact this practice should be avoided, as it may increase the risk of infection.<sup>3</sup> Long hair may be clipped or cut with scissors if it interferes with suturing, or alternatively, it may be moistened with antibiotic cream and combed away from the wound. The eyebrows should never be shaved or clipped, as regrowth is unpredictable.<sup>3</sup>

Next, anesthetize the tissues using the preferred local anesthetic and a 25-to-30-gauge needle. Place the needle directly into the exposed subcutaneous tissue at one end of the laceration, pull back on the plunger to ensure that the needle has not entered the intravascular space, and then slowly inject anesthetic as you advance the needle. You should inject the anesthetic in the plane between the dermis and subcutaneous tissue, because this location offers less resistance and is less painful than is an approach in which you pierce the epidermis and inject the anesthetic directly into the dermis.<sup>3</sup> Begin subsequent injections in regions already anesthetized. The pain of the anesthetic injection can be lessened by using small needles, injecting the agent slowly, warming the anesthetic to body temperature, and buffering the solution with sodium bicarbonate in a 1:10 ratio.<sup>1</sup>

After the anesthetic has taken effect (usually within 2 minutes), most wounds should be irrigated with normal saline solution. (Some evidence suggests that irrigation with tap water may be equally efficacious.<sup>2</sup>) Irrigation is not required, and may in fact be detrimental, in wounds involving highly vascular, loose areolar tissues such as the eyebrow.<sup>2</sup> The risk of infection is low in such areas, and high-pressure irrigation may distort the delicate tissues, making repair difficult. In such situations, gentle scrubbing is a preferred substitute to vigorous irrigation.

Vigorous irrigation with a 30- or 60-ml syringe and splash guard is required to provide adequate pressure for mechanical débridement. Irrigate the wound until it is visibly clean; the amount of irrigant required will vary, depending on the size of the laceration and the degree of contamination.

Switch to sterile gloves and apply a sterile fenestrated drape over the wound. Using a forceps or needle holder, carefully explore the wound, looking for foreign material and injury to tendons, nerves, vessels, or other underlying structures. Ensure that the wound area is well illuminated with an overhead light during the exploration. Consult a specialist if there is any question of serious injury to the underlying structures. Remove any devitalized tissue by sharp dissection (using a scalpel or iris scissors) before beginning laceration repair.



Proper way to grip the instruments

#### LACERATION REPAIR

Hold the needle holder in the palm of your dominant hand, with your index finger extended. Do not put your fingers into the holes of the needle holder while placing sutures.<sup>3</sup> This approach allows for maximum control and proper angle of entry into the epidermis (see below). You may place your fingers in the holes to release the needle and to tie knots. Hold the toothed forceps in your nondominant hand the way you would hold a pencil. Grasp the needle with the very tip of the needle holder at the junction of the proximal and middle third of the needle at a 90-degree

angle. Be careful not to grab the distal tip of the needle or the proximal end that is clamped around the suture material, because doing so may blunt the needle or loosen the bond of the thread to the needle, respectively.

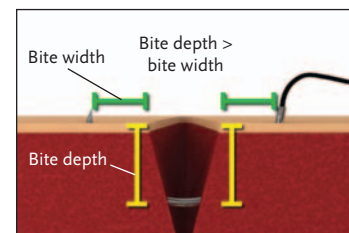
Position yourself so that the laceration is parallel to the frontal plane of your body. Place the first stitch in the center of the wound, so that it bisects the laceration. Use the forceps to gently evert the wound edge opposite you. Do not pinch the tissue between the tips of the forceps, because this may injure it. Pronate your wrist, and insert the needle into the skin at a 90-degree angle. Then, supinate your wrist to drive the needle in a curvilinear path through the dermis and subcutaneous tissues into the center of the laceration. At this point, temporarily secure the area just below the exposed tip of the needle with the forceps, and then grasp it with the needle holder, before again supinating your wrist to complete the first half of the stitch. Repeat the process on the opposite side of the laceration, first everting the wound edge with the forceps and then driving the needle through the tissues by supinating your wrist. During suture placement, make sure that the bite width and the bite depth are the same on each side of the laceration. Ideally, the bite depth should be greater than the width. By following these principles, you will create sutures that follow a curvilinear path through the tissues and the subcutaneous layers will be properly aligned, resulting in eversion of the wound edge. Eversion is necessary for proper healing and results in the best possible cosmetic outcome.<sup>3</sup> Finally, pull the suture material through the wound so that a 3-cm tail remains on the entry side.

To begin the first knot, place the needle holder parallel to, and over, the wound. Hold the needle end of the suture with your nondominant hand, allowing the needle to rest on the sterile drape. Next, wrap the suture over the needle holder twice. This forms the surgeon's knot, which prevents the first "throw" from loosening. Rotate the needle holder 90 degrees, grasp the free end of the suture, and then use your hands to pull the two ends in opposite directions across the laceration, tightening the knot only enough to approximate the wound edges. Begin the second throw by again placing the needle holder parallel over the laceration. On this and all subsequent throws, wrap the suture over the needle holder only once before grasping the free end with the needle holder and tightly securing the knot. Place a total of four throws. After the final throw, pull the knot off to one side of the laceration, so that it does not lie on top of the approximated wound edges. This prevents the knot from being incorporated into the coagulum that forms during healing and thus facilitates wound healing as well as suture removal. Cut the suture with the scissors, leaving tails of approximately 1 cm.

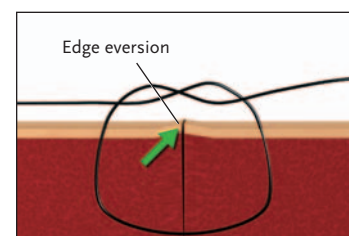
Continue the repair by placing additional sutures, each time bisecting segments along the laceration. This approach facilitates proper alignment of the wound edges. As the edges become approximated, you may place sutures in a single pass, without having to first come up through the center of the wound.

No steadfast rules exist regarding the number of sutures required for a given length of laceration. A sufficient number of sutures should be placed so that all gaps in the wound edges are eliminated. Generally, the space between sutures is approximately equal to the bite width.<sup>3</sup> If during the process of repair a particular suture is malpositioned or incorrectly spaced, it may be removed and replaced with a more suitable stitch.

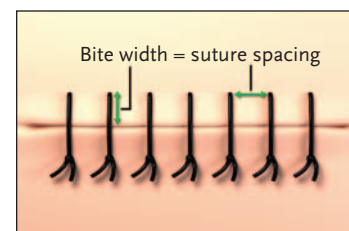
Once finished, remove the drape and wipe off the antiseptic solution. Activate safety devices such as needle caps, and dispose of all of the instruments and needles in appropriate biohazard containers.



Proper placement of a suture



Proper knot placement



Proper number and spacing of sutures

**FOLLOW-UP**

Cover repaired lacerations (except those on the face and scalp) with a sterile, non-adherent dressing. The use of topical antibiotics and creams is of limited benefit and is not mandatory; however, they should be used on uncovered wounds, in order to maintain a moist environment. The use of dressings and topical antibiotics prevents wound desiccation, which impedes reepithelialization.<sup>2,3</sup> Instruct the patient to change the dressing daily.

Assess the patient's tetanus-immunization status. Administer tetanus prophylaxis (tetanus and diphtheria toxoids in children and tetanus toxoid, reduced diphtheria toxoid, and acellular pertussis vaccine in patients 19 to 64 years of age) if the last dose was given more than 10 years earlier. For contaminated or extensive injuries, the recommended dosing interval is 5 years. Tetanus immune globulin should also be given to patients with grossly contaminated or extensive wounds if no previous tetanus prophylaxis has been given.<sup>3</sup>

Prophylactic antibiotics are not needed for simple, clean lacerations; however, they may be beneficial in extenuating circumstances, such as in patients with grossly contaminated wounds, crush injuries, open fractures, tendon injuries, bite wounds, or immunosuppression.<sup>1,3</sup> Antibiotics with coverage against gram-positive organisms (such as first-generation cephalosporins) are adequate for most wounds. Broader coverage, such as the addition of an aminoglycoside for open fractures or the use of amoxicillin with clavulanic acid for bite wounds, should be provided depending on the clinical scenario.<sup>1</sup>

Provide the patient with written wound-care instructions, including ways to spot signs of infection. Instruct the patient to keep the wound dry for 12 to 24 hours. Subsequently, the patient should be encouraged to wash the wound gently with soap and water. Prolonged immersion in water should be minimized. You should review the proper application of dressings and topical creams with the patient, and instruct the patient to avoid exposing the healing wound to direct sunlight for 6 to 12 months, since such exposure could cause hyperpigmentation of the scar.

The timing of suture removal depends largely on the location of the wound. Facial sutures should be removed within 5 days to prevent scarring. Sutures placed in the scalp, torso, arms, legs, hands, or feet should be removed within 7 to 10 days. Sutures subject to a substantial degree of tension, such as those overlying joints, benefit from being left for a longer interval and should be removed in 10 to 14 days.<sup>1</sup>

**COMPLICATIONS**

Early complications of laceration repair include infection and wound dehiscence. Early follow-up with a wound check in 24 to 48 hours should be arranged if the possibility of these complications is an issue at the time of primary repair. Additional complications include a retained foreign body, unrecognized deep-structure injury, and scar formation.

**REFERENCES**

1. Singer AJ, Hollander JE, Quinn JV. Evaluation and management of traumatic lacerations. *N Engl J Med* 1997;337:1142-8.
2. Hollander JE, Singer AJ. Laceration management. *Ann Emerg Med* 1999;34:356-67.
3. Trott AT. Wounds and lacerations: emergency care and closure. 3rd ed. Philadelphia: Elsevier, 2005.
4. Edlich RF, Rodeheaver GT, Thacker JG. Methods for wound closure. In: Tintinalli JE, Ruiz E, Krome RL, eds. *Emergency medicine: a comprehensive study guide*. 4th ed. New York: McGraw-Hill, 1996:283-90.

Copyright © 2006 Massachusetts Medical Society.